

## Case Report

# Kinking, Aneurysm and Tortuosity of Common Iliac arteries in two Cadaver

<sup>1</sup>Dr. Purnendu Rang , <sup>2</sup>Dr. Champak Kumar Dey , <sup>3</sup>Dr. Asutosh Pramanik , <sup>4</sup>Dr. Arunima Nag (Ray) , <sup>5</sup>Dr. Dipankar Bhoumik , <sup>6</sup>Dr. Anupam Baske , <sup>7</sup>Dr. Biswapriya Sinha , <sup>8</sup>Prof. (Dr.) Sudeshna Majumdar

<sup>1</sup>Junior Resident, Department of Anatomy, North Bengal Medical College, Sushrutanagar, Darjeeling – 734012. West Bengal, India.

<sup>2</sup>Demonstrator, Department of Anatomy, North Bengal Medical College, Sushrutanagar, Darjeeling – 734012. West Bengal, India.

<sup>3</sup>Junior Resident, Department of Anatomy, North Bengal Medical College, Sushrutanagar, Darjeeling – 734012. West Bengal, India.

<sup>4</sup>Junior Resident, Department of Anatomy, North Bengal Medical College, Sushrutanagar, Darjeeling – 734012. West Bengal, India.

<sup>5</sup>Assistant Professor, Department of Anatomy, North Bengal Medical College, Sushrutanagar, Darjeeling – 734012. West Bengal, India.

<sup>6</sup>Junior Resident, Department of Anatomy, North Bengal Medical College, Sushrutanagar, Darjeeling – 734012. West Bengal, India.

<sup>7</sup>Demonstrator, Department of Anatomy, North Bengal Medical College, Sushrutanagar, Darjeeling – 734012. West Bengal, India.

<sup>8</sup>Professor and Head of the Department of Anatomy, North Bengal Medical College, Sushrutanagar, Darjeeling – 734012.

Corresponding author: Prof. (Dr.) Sudeshna Majumdar

---

### Abstract:

In January, 2016, while doing the routine dissection for MBBS Students, in the Department of Anatomy, North Bengal Medical College, West Bengal, few variations were found in the Common Iliac Arteries in two male cadavers (seventy and seventy-five year old). In the first cadaver (seventy year old), the left common iliac artery had a kinking. In the second cadaver (seventy-five year old) the lower part of the abdominal aorta was a bit tortuous, the left common iliac artery had a kinking, the right common iliac artery was tortuous and had one aneurysm.

This case report will help us to enhance our knowledge in gross and clinical Anatomy. Moreover, the prevalence of the aneurysm, tortuosity and kinking of abdominal aorta and iliac arteries is important for are important for optimizing radiation doses, endovascular stent grafting or traditional Surgery.

**Key Words:** Abdominal aorta, common iliac artery, kinking, tortuosity, aneurysm

---

## **Introduction**

The abdominal aorta begins at the aortic hiatus of the diaphragm, anterior to the twelfth thoracic vertebra. It descends anterior to the lumbar vertebrae and bifurcates into right and left common iliac arteries antero-lateral to the 4<sup>th</sup> lumbar vertebral bodies. The angle of bifurcation is variable [1]. These arteries diverge as they descend and divide at the level of the sacro-iliac joint into internal and external iliac arteries [2]. The external iliac artery is the principal artery of the lower limb and the internal iliac artery provides the principal supply to the walls and viscera of the pelvis, the perineum and the gluteal region [2].

**Right Common Iliac Artery:** This artery is approximately 5cm. long. It passes obliquely across the part of the 4<sup>th</sup> and 5<sup>th</sup> lumbar bodies and is crossed anteriorly by the sympathetic chain to the pelvic plexus and at its point of bifurcation, by the ureter [2].

**Left Common Iliac Artery:** This artery is approximately 4cm. long. Lying anterior to it are the sympathetic rami to the pelvic plexus, the superior rectal artery and anterior to its terminal bifurcation lie the ureter. The sympathetic trunk, the fourth and fifth lumbar vertebrae and intervening intervertebral discs, the obturator nerve, the lumbosacral trunk and the iliolumbar artery are all posterior [2].

## **Aims and objectives**

The course and variations of the abdominal aorta and common iliac arteries were studied in this case report to enhance our knowledge in gross and clinical Anatomy.

## **Materials and methods**

During the routine dissection for undergraduate students in the Department of Anatomy, North Bengal Medical College, West Bengal, variations were found in the Common Iliac Arteries in two male cadavers ( seventy and seventy-five year old). Dissection was done minutely in the abdomen and pelvic cavity. Structures were observed in details , relevant photographs were taken.

## **Observations**

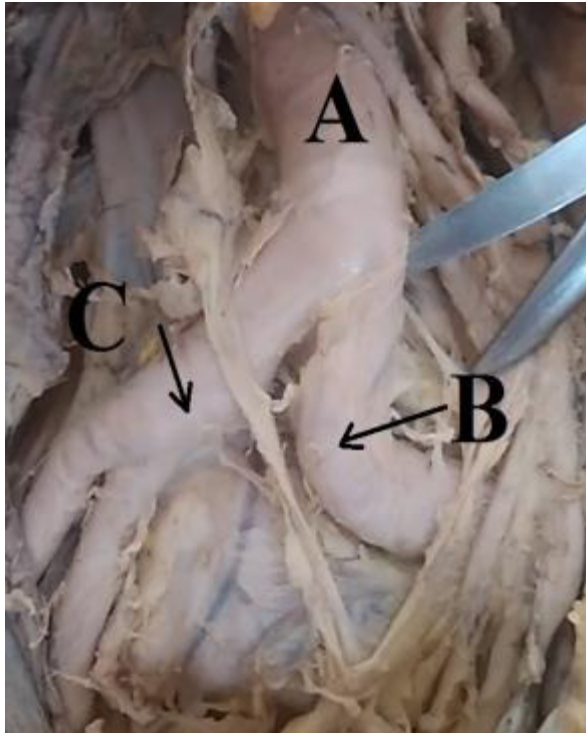
In the first cadaver (seventy year old), the left common iliac artery had a kinking, but the right common iliac artery had no such variation. Both the common iliac arteries divided into external and internal iliac arteries.

In the second cadaver (seventy-five year old) the lower part of the abdominal aorta was a bit tortuous, the left common iliac artery had a kinking, the right common iliac artery was tortuous and had one aneurysm in lower part.

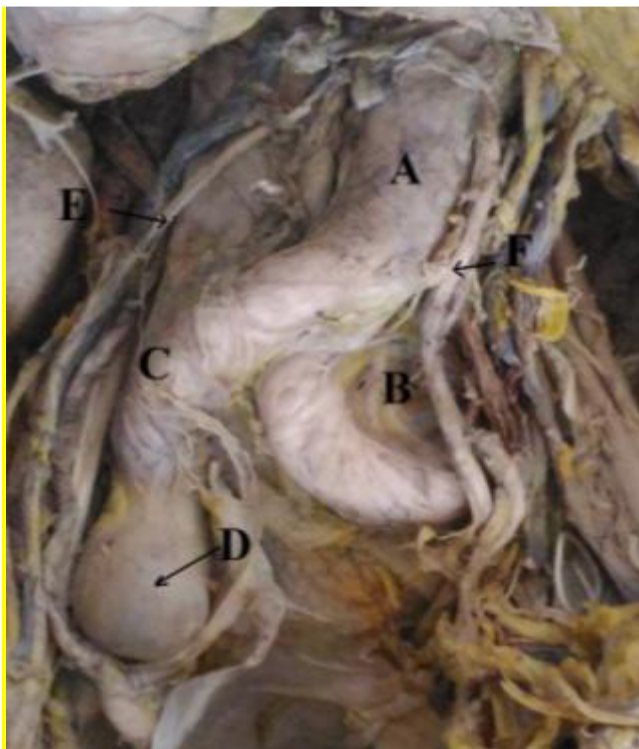
The left common iliac arteries of both the cases had 'S' shaped kinking.

**Medworld asia**

**Dedicated for Scientific research**



**Figure – 1;** The abdominal aorta (A) divided into right and left common iliac arteries (B& C), whereas, the left common iliac artery had a kinking (B) in the first cadaver.



**Figure – 2;** The abdominal aorta (A) was a bit tortuous in the second cadaver. The left common iliac artery (B) had a kinking. The right common iliac artery (C) was tortuous and it had one aneurysm (D). The right and left ureters (E & F) are also visible,

## Discussion

According to a study conducted by Boonruangsri et al, the tortuosity of common and external iliac arteries were prevalent in 1.76 and 20% cases. No tortuosity of internal iliac artery was observed in that study and the percentage of kinking (may be of 'S' shaped, reversed, low grade or 'V' shaped) of common, external, and internal iliac arteries were 4.71, 16.47, and 1.18%, respectively [3]. In their study they observed all abnormal types of abdomino-iliac arteries in Thai cadavers and found the aneurysm, tortuosity, kinking of abdomino-iliac arteries (except external arteries) in less than 10 percent cases. To consider the tortuosity, the angle of the artery was greater than 130 degrees whereas kinking angle was lesser than 130 degrees [3]. The left common iliac arteries of both the present cases concerned had 'S' shaped kinking.

In the elderly, the abdominal aorta frequently becomes elastic and tortuous, changing the angle and position of bifurcation. Approximately 80% of abdominal aortic aneurysms occur in the infrarenal segments of aorta. Men with atherosclerotic conditions are most at risk of developing the condition, particularly from the 6<sup>th</sup> decade [1].

Unlike abdominal and combined aortoiliac artery aneurysms, Isolated Iliac Artery

Aneurysms (IIAAs) are uncommon. An isolated iliac artery aneurysm is defined as a twofold increase in the diameter of the iliac artery without a coexisting aneurysm at another location. IIAA was encountered infrequently in the past, comprising 0.9% to 4.7% of all intraabdominal aneurysms. In recent times, many asymptomatic IIAAs have been detected incidentally because of the widespread use of abdominal ultrasonography and computed tomography [ 4, 5, 6, 7]. The frequency of IIAA compared to that of

abdominal aortic aneurysm (AAA) ranges from 5.1% to 19.4% [ 7, 8].

Iliac artery aneurysms (IAAs) participate in various aortoiliac aneurismal (AIA) patterns that frequently necessitate sophisticated reconstructions. An IAA represents a 50% arterial diameter increase, compared to normal; in absolute terms, common iliac arteries (CIAs) are considered aneurismal with diameter > 18.5mm for men (normal: 1.23 ± 0.20 cm) and >15mm for women (normal: 1.02 ± 0.19 cm); internal iliac artery's (IIA) diameter, in both genders, is 0.54 ± 0.15 cm [9, 10, 11]. Occasionally, a CIAA looms as an abdominal aortic aneurysm (AAA) extension; coexistence of uni- or bilateral ectasia or concomitant IAA and AAA approximates 20–40% [11, 12]. Isolated IAAs (prevalence 0.008–0.03% represent 2– 11% of intra-abdominal aneurysms [11, 13]. Isolated CIAAs are found in 70% of isolated IAAs (20% are IIAAs), being frequently (30–50%) bilateral and 50–85% asymptomatic on diagnosis [11].

The CIAAs expansion rate is 0.29 cm/y; as no rupture a CIAA < 3.8 cm has been reported, elective repair of asymptomatic patients with CIAA ≥ 3.5 cm seems justified [11, 14]. External iliac artery aneurysms (EIAAs) consist < 10% of isolated IAAs; isolated IIAAs represent 0.4%–1.9% of arterial aneurysms and 0.04% of AIAs , with 38% rupture incidence at presentation and 58–80% mortality rate [11, 15].

According to Rai et al, Isolated iliac artery aneurysms without associated abdominal aortic aneurysms are rare. Incidence varies between 0.03% and 0.1%. Deep pelvic location of aneurysms, make their detection by physical examination very difficult. Usually they remain asymptomatic until ruptured. Other symptoms and signs are due to local

compression of adjacent pelvic structure [16]. They found a large unruptured isolated iliac artery aneurysm in one 70 year old male patient with the complaint of gradually increasing pulsatile mass in right iliac fossa since 3 years with intermittent burning in micturition since 2 years. It was a rare presentation [16].

Mistry and Bashir stated that Isolated iliac artery aneurysm are uncommon, accounting for <2% of abdominal aneurysms. The common iliac artery is most commonly involved (70%), whereas the internal iliac artery is involved in 25%. Iliac artery aneurysms are bilateral in approximately 30% cases [17, 18, 19]. Treatment of aortoiliac artery aneurysm is commonly the open surgical repair or endovascular stenting (endovascular aneurysm repair) [1].

The prevalence of the aneurysm, tortuosity and kinking of abdominal aorta and iliac arteries is important for primary consideration in operative planning. Recognitions of these phenomena are important for optimizing radiation doses, endovascular stent grafting or traditional Surgery [3].

#### **Conclusion**

This case report regarding the tortuosity, kinking and aneurysm of abdominal arteries will help us to enhance our knowledge in gross anatomy and will be of help for surgical, radiological or other clinical interventions in abdomen and pelvis.

**Acknowledgement:** We are grateful to all the members of the Department of Anatomy, North Bengal Medical College, West Bengal, for their cordial help regarding this case report.

#### **References**

1. Standring S, Stringer MD, Smith AL, Weins AJ, Pitman AG, Mars D. In: Gray's Anatomy, The Anatomical Basis of Clinical Practice. Posterior abdominal wall and retroperitoneum. 41th Edition (Indian Edition). Elsevier. 2016: 1087 - 1088.
2. Standring S, Borely NR, Healy JC, Collins P, Wigley C, Khan N, Moore LA (editors). In: Gray's Anatomy, The Anatomical Basis of Clinical Practice. True Pelvis, Pelvic floor and perineum. 40th Edition. Spain, Philadelphia; Churchill Livingstone Elsevier. 2011: 1086 - 1088.
3. Boonruangsri P, Suwannapong B, Rattanasuwan S & Iamsaard S. Aneurysm, tortuosity, and kinking of abdominal aorta and iliac arteries in Thai cadavers. *Int. J. Morphol.*, 33(1):73-76, 2015.
4. Lowry SF & Kraft RO. Isolated aneurysms of the iliac artery. *Arch Surg* 1978;113:1289-93.
5. Mc Cready RA. Isolated iliac artery aneurysms. *Surgery* 1983;93:688-93.
6. Nachbur BH. Isolated iliac aneurysms. *Eur J Vasc Surg* 1991;5:375-81.
7. Shinichi Hiromatsu, Atsuhisa Tanaka and Kentarou Sawada. Isolated Iliac Artery Aneurysm. Diagnosis, Screening and Treatment of Abdominal, Thoracoabdominal and Thoracic Aortic Aneurysms. On Research Gate, the professional network of scientists; September 12, 2011; p : 293-300. [www.intechopen.com](http://www.intechopen.com)
8. Kasirajan V. Management of isolated common iliac artery aneurysms. *Cardiovasc Surg*, 1998; 6:171- 7.
9. Johnston KW, Rutherford R B, Tilson MD, Shah DM, Hollier L and Stanley J C. Suggested standards for reporting on arterial aneurysms. Subcommittee on Reporting Standards for Arterial Aneurysms. Society for

- Vascular Surgery and North American Chapter, International Society for Cardiovascular Surgery, *Journal of Vascular Surgery*, 1991, vol. 13, pp. 452–458.
10. Horejs D, Gilbert P M, Burstein S and Vogelzang R L. Normal aortoiliac diameters by CT. *Journal of Computer Assisted Tomography*, 1988, vol. 12, no. 4, pp. 602–603.
  11. Kotsis T, Louizos L A, Pappas E and Theodoraki K. Complex Common and Internal Iliac or Aortoiliac Aneurysms and Current Approach: Individualised Open-Endovascular or Combined Procedures. *International Journal of Vascular Medicine*. Volume 2014, Article ID 178610, 14 pages.  
<http://dx.doi.org/10.1155/2014/178610>
  12. Hobo R, Sybrandy JEM., Harris P L and Buth J. Endovascular repair of abdominal aortic aneurysms with concomitant common iliac artery aneurysm: outcome analysis of the EUROSTAR experience. *Journal of Endovascular Therapy*, 2008, vol. 15, no. 1, pp. 12–22.
  13. Brunkwall J, Hauksson H, Bengtsson D, Bergqvist R, Takolander and Bergentz S-E., Solitary aneurysms of the iliac artery system: an estimate of their frequency of occurrence, *Journal of Vascular Surgery*. 1989, vol. 10, no. 4, pp. 381–384,
  14. Huang Y, Gloviczki P, Duncan A A et al., Common iliac artery aneurysm: expansion rate and results of open surgical and endovascular repair. *Journal of Vascular Surgery*, 2008. vol. 47, no. 6, pp. 1203–1210,.
  15. Krupski W C, Selzman C.H, Florida R, Strecker P K, Nehler M R and Whitehill T A. Contemporary management of isolated iliac aneurysms. *Journal of Vascular Surgery*, 1998, vol. 28, no. 1, pp. 1–13.
  16. Rai N, Sarkar UN, Das D, Dutta S, Srivastava DK, Mahapatra SS. A large unruptured isolated iliac artery aneurysm:rare presentation. *Indian J Thorac Cardiovasc Surg*; 2010, 26:222–224.
  17. Mistry KA and Dr Omar Bashir O. Iliac artery aneurysm. *Radiology Reference Article*; 2016: 1-2  
[Radiopaedia.org](http://Radiopaedia.org)
  18. Uberoi R, Tsetis D, Shrivastava V et al. Standard of practice for the interventional management of isolated iliac artery aneurysms. *Cardiovasc Intervent Radiol*. 2011;34 (1): 313.
  19. Sakamoto I, Sueyoshi E, Hazama S et al. Endovascular treatment of iliac artery aneurysms , *Radiographics*. 2005; 25 Suppl 1 : S21327.